

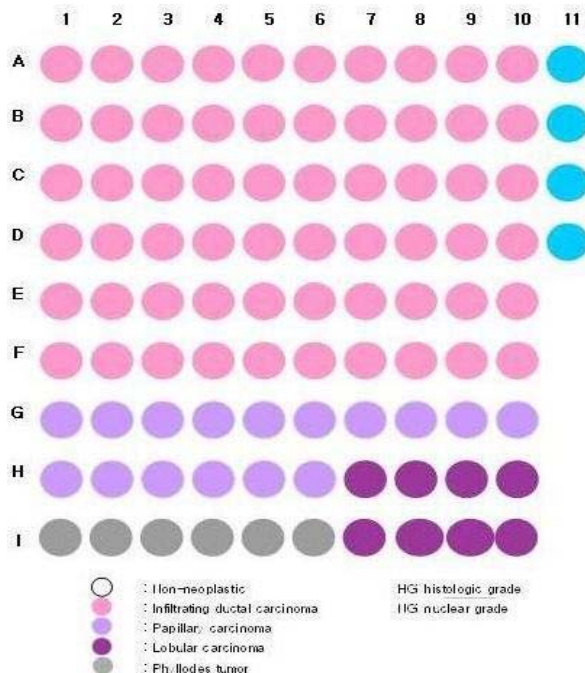
Specifications:

- No. of cases: 45
- Tissue type: Breast cancer tissues
- No. of spots: 2 spots from each cancer case (90 spots)
4 non-neoplastic spots (4 spots)
- Total spots: 94
- Corresponding normal tissues with cancers: Yes
- Diameter: 1.0 mm

Documents:

- Product specification: layout, summary of tissue spots
- H&E stained images
- Detailed pathological information

Layout:



Summary of tissue spots

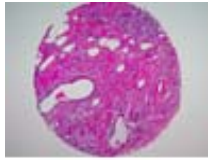
No.	Coordinate	Sex	Age	Key Word	HG	NG	TNM Stage	
1	A	1,2	f	44	Infiltrating ductal carcinoma	1	2	T1cN0M0 (I)
2		3,4	f	59	Infiltrating ductal carcinoma	1	2	T1cN0M0 (I)
3		5,6	f	41	Infiltrating ductal carcinoma	1	2	T1cN1M0 (II A)
4		7,8	f	46	Infiltrating ductal carcinoma	1	2	T2N0M0 (II A)
5		9,10	f	33	Infiltrating ductal carcinoma	1	2	T1cN1aM0 (II A)
6		11			Non-neoplastic from C1,2			
7	B	1,2	f	70	Infiltrating ductal carcinoma	1	2	
8		3,4	f	40	Infiltrating ductal carcinoma	1	3	T2N1bM0 (II B)
9		5,6	f	67	Infiltrating ductal carcinoma	1	3	T2N0M0 (II A)
10		7,8	f	45	Infiltrating ductal carcinoma	1	3	T3N2aM0 (III A)
11		9.1	f	67	Infiltrating ductal carcinoma	1	3	T2N0M0 (II A)
12		11			Non-neoplastic from E7,8			
13	C	1,2	f	67	Infiltrating ductal carcinoma	1	3	T2N1aM0 (II A)
14		3.4	f	34	Infiltrating ductal carcinoma	2	1	TxN2aM0 (III)
15		5.6	f	36	Infiltrating ductal carcinoma	2	1	T1cN0M0 (I)
16		7.8	f	62	Infiltrating ductal carcinoma	2	1	T1cN0M0 (I)
17		9,10	f	67	Infiltrating ductal carcinoma	2	2	T2N1aM0 (II B)
18		11			Non-neoplastic from F7,8			
19	D	1,2	f	42	Infiltrating ductal carcinoma Mucinous carcinoma	2	2	T1cN0M0 (I)
20		3,4	f	46	Infiltrating ductal carcinoma	2	2	T1bN0M0 (I)
21		5,6	f	66	Infiltrating ductal carcinoma	2	2	T2N0M0 (II A)
22		7,8	f	54	Infiltrating ductal carcinoma	2	2	T2N0M0 (II A)
23		9,10	f	38	Infiltrating ductal carcinoma	2	2	T3N2aM0 (III A)
24		11			Non-neoplastic from G1,2			
25	E	1,2	f	61	Infiltrating ductal carcinoma			T1cN2aM0 (III A)
26		3,4	f	37	Infiltrating ductal carcinoma	2	2	T2N3M0 (III C)
27		5,6	f	35	Infiltrating ductal carcinoma	3	1	T1cN3aM0 (III C)
28		7,8	f	36	Infiltrating ductal carcinoma Comedocarcinoma	3	1	T1cN1aM0 (II A)
29		9,10	f	36	Infiltrating ductal carcinoma	3	1	T2N0M0 (II A)
30	F	1,2	f	47	Infiltrating ductal carcinoma	3	1	T2N3aM0 (III C)
31		3.4	f	37	Infiltrating ductal carcinoma	3	1	T2N0M0 (II A)
32		5.6	f	64	Infiltrating ductal carcinoma Apocrine carcinoma	3	1	T2N1aM0 (II B)
33		7,8	f	34	Infiltrating ductal carcinoma	3	2	T1cN1aM0 (II A)
34		9,10	f	37	Infiltrating ductal carcinoma			T2N0M0 (II A)

Summary of tissue spots

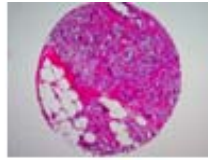
No.	Coordinate	Sex	Age	Key Word	HG	NG	TNM Stage	
35	G	1,2	f	40	Invasive ductal carcinoma Papillary carcinoma	2		T2N0M0 (II A)
36		3,4	f	42	Papillomatosis Papillary carcinoma Ductal carcinoma in-situ			T2N0M0 (II A)
37		5,6	m	75	Papillary carcinoma			T4bN0M0 (III B)
38		7,8	f	41	Papillary carcinoma			T1cN0M0 (I)
39		9.1	f	40	Ductal carcinoma in-situ Papillary carcinoma			T1bN0M0 (I)
40	H	1,2	f	61	Intraductal carcinoma Papilloma Ductal carcinoma in-situ Papillary carcinoma			TxN0M0
41		3,4	f	62	Papillary carcinoma			T1cN0M0 (I)
42		5,6	f	62	Papillary carcinoma	2,3	2,3	T4aN1M0 (III B)
43		7,8	f	55	Infiltrating lobular carcinoma			T2N0M0 (II A)
44		9,10	f	78	Infiltrating lobular carcinoma			T1cN0M0 (I)
45	I	1,2	f	43	Cystosarcoma phyllodes Phyllodes tumor Malignant tumor			
46		3,4	f	37	Phyllodes tumor			
47		5,6	f	35	Phyllodes tumor Cystosarcoma phyllodes malignant			
48		7,8	f	54	Infiltrating lobular carcinoma			T1cN1aM0 (II A)
49		9,10	f	43	Infiltrating lobular carcinoma			T1cN2aM0 (III A)

QC sheet_LOT#122120404131

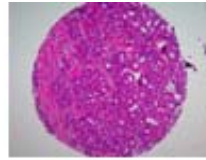
Hematoxylin and Eosin staining



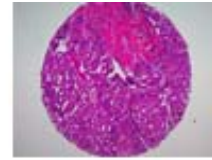
A1



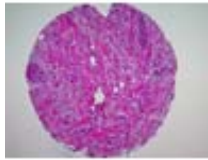
A2



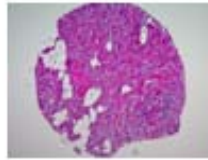
A3



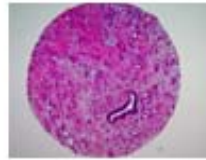
A4



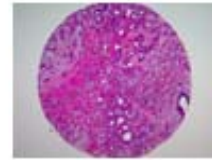
A5



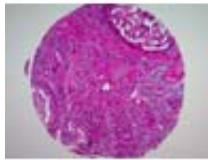
A6



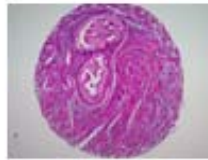A7



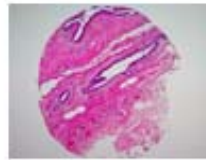A8



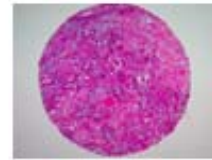
A9



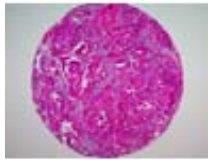
A10



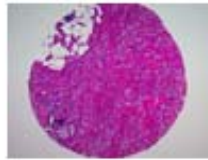A11



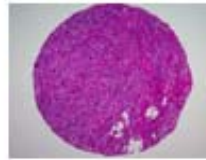
B1



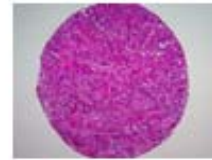
B2



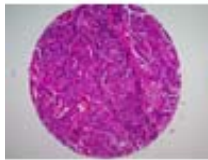
B3



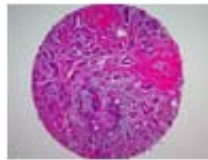B4



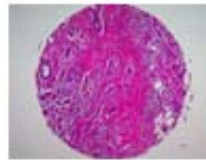
B5



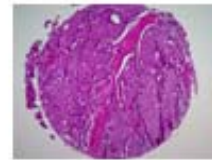B6



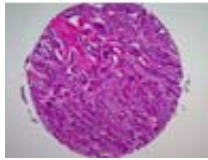
B7



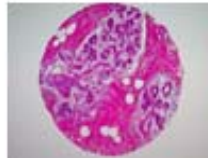
B8



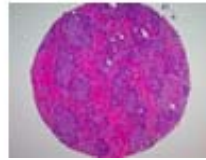
B9



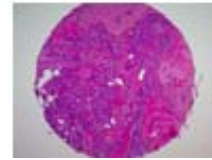
B10



B11

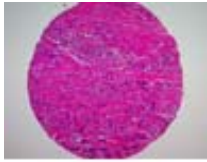


C1

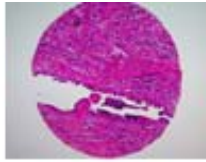


C2

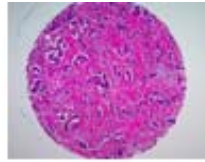
QC sheet_LOT#122120404131
Hematoxylin and Eosin staining



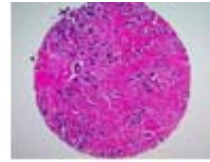
C3



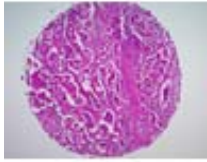
C4



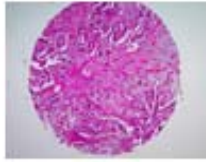
C5



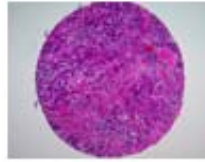
C6



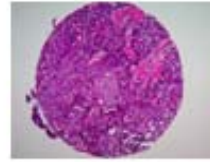
C7



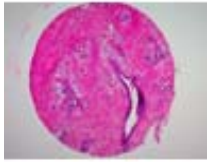
C8



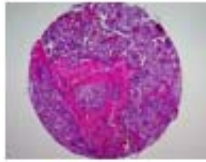
C9



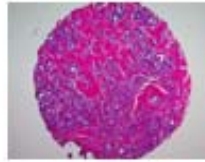
C10



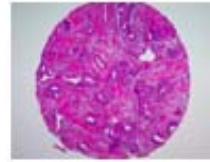
C11



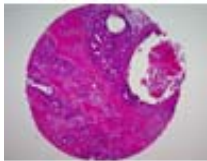
D1



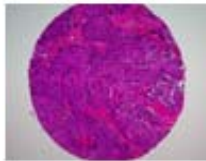
D2



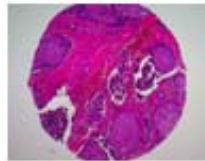
D3



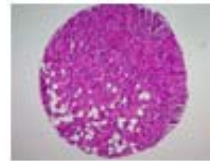
D4



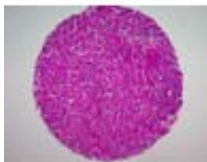
D5



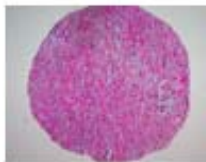
D6



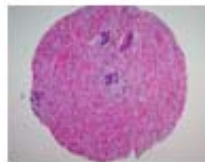
D7



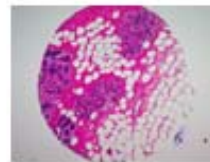D8



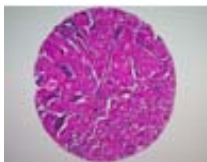D9



D10



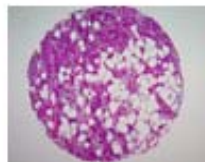
D11



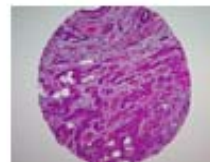E1



E2

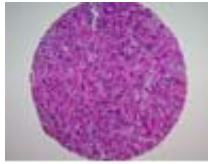


E3

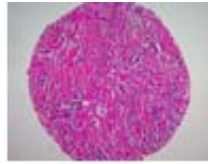


E4

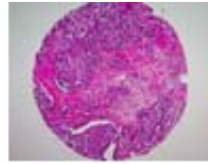
QC sheet_LOT#122120404131 Hematoxylin and Eosin staining



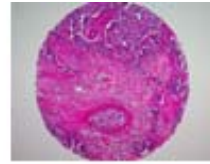
E5



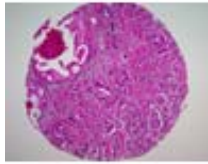
E6



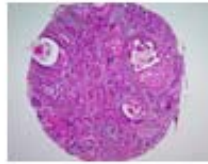
E7



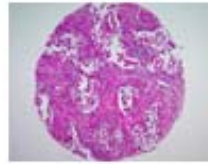
E8



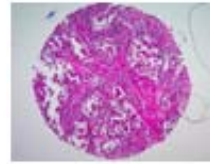
E9



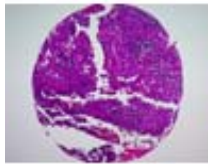
E10



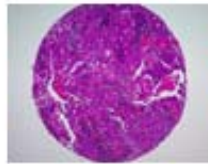
F1



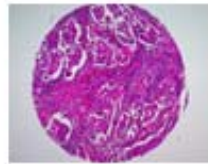
F2



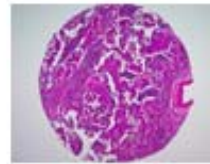
F3



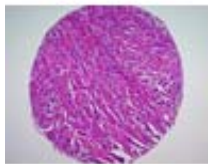F4



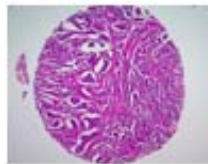
F5



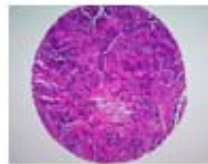
F6



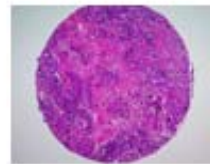
F7



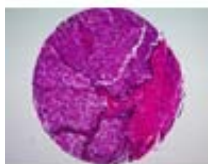F8



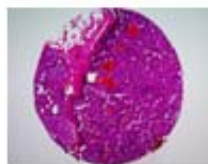
F9



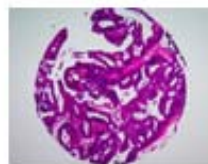F10



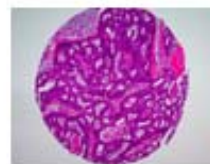
G1



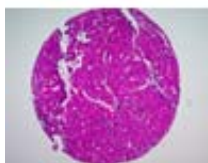
G2



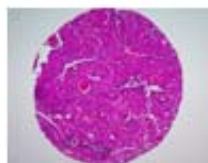
G3



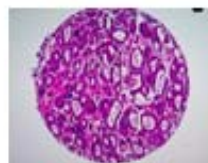G4



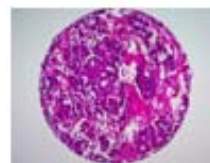G5



G6

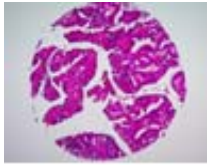

G7

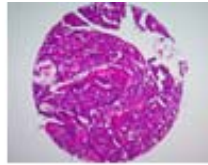


G8

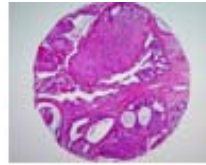
QC sheet_LOT#122120404131
Hematoxylin and Eosin staining



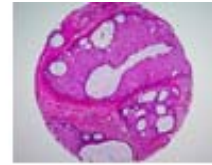G9



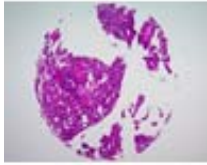
G10



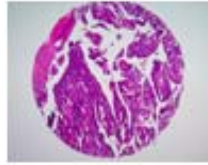
H1



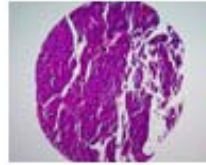
H2



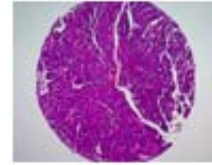
H3



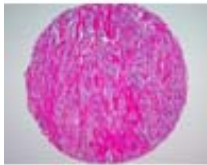H4



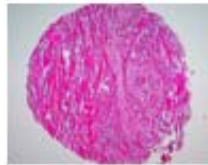
H5



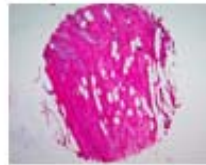H6



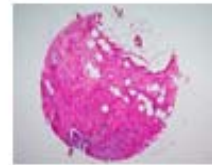
H7



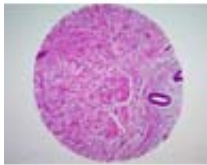
H8



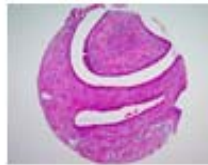
H9



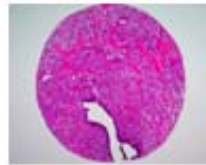
H10



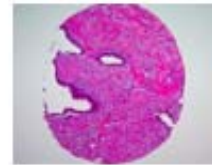
I1



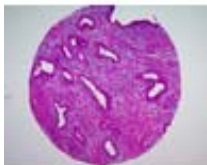I2



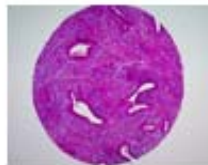
I3



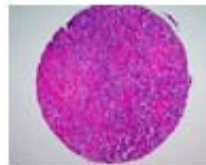
I4



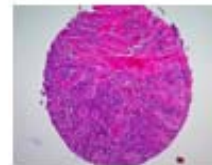
I5



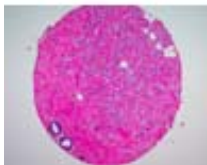
I6



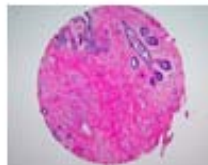
I7



I8



I9



I10

A202 (II): Breast cancer tissues

No.	Coordinate		Sex	Age	Key Word	Histological Diagnosis	HG	NG	TNM Stage	IHC
1	A	1,2	f	44	Infiltrating ductal carcinoma	Breast, right, lumpectomy: 1) infiltrating ductal carcinoma, nuclear grade 2, Histologic grade I with minimal intraductal component (less than 5%) 2) intraductal papillomatosis 3) resection margins, superior, inferior and lateral: free of tumor 4) resection margins, labelled as "new margin(medial)": - free of carcinoma - focal presence of atypical ductal hyperplasia in superomedial side	1	2	T1cN0M0 (I)	ER:+ PR: + C erb B2: -
2	A	3,4	f	59	Infiltrating ductal carcinoma	Breast, left, frozen excision: Infiltrating ductal carcinoma, nuclear grade 2, Histologic grade I with intraductal component, 10%	1	2	T1cN0M0 (I)	ER:+ PR: + C erb B2: -
3	A	5,6	f	41	Infiltrating ductal carcinoma	Breast, left, modified radical mastectomy: Status post excisional biopsy(see F2002-549, 550) with a residual and separate infiltrating ductal carcinoma 1) size: 1.6x1.0x1.0 cm 2) black's nuclear grade 2 (moderately differentiated) 3) modified Bloom-Richardson's histological grade I (tubule formation: 2, nuclear pleomorphism: 2, mitosis: 1) 4) no vascular invasion 5) intraductal component: about 5% 6) nipple and areola: free of tumor 7) overlying skin: free of tumor 8) underlying fascia: free of tumor 9) regional lymph node, axillary (1/20), level II (0/0) : (1/20): metastatic adenocarcinoma in one out of 20 nodes (size of metastasis: 6 mm) with focal pericapsular extension(pN1biii)	1	2	T1cN1M0 (II A)	ER:+ PR: + C erb B2: -

A202 (II): Breast cancer tissues

No.	Coordinate		Sex	Age	Key Word	Histological Diagnosis	HG	NG	TNM Stage	IHC
4	A	7,8	f	46	Infiltrating ductal carcinoma	Breast, left, modified radical mastectomy: Infiltrating ductal carcinoma with 1) black's nuclear grade 2(moderately differentiated) 2) modified Bloom-Richardson's histological grade I (tubule formation 1, nuclear pleomorphism 2, mitosis: 1) 3) areas of tubular carcinoma and cribriform carcinoma 4) associated with extensive ductal carcinoma in situ (micropapillary, clinging type) and columnar cell changes 5) nipple and areola: Dermal involvement of infiltrating ductal carcinoma 6) underlying fascia: Involvement of ductal carcinoma in situ 7) regional lymph node, axillary (0/18), level II (0/4) : (0/22): free of tumor	1	2	T2N0M0 (II A)	ER:- PR:- C erb B2: -
5	A	9,10	f	33	Infiltrating ductal carcinoma	Breast, right, total mastectomy: Infiltrating ductal carcinoma with prominent tubular differentiation 1) black's nuclear grade 2 (moderately differentiated) 2) modified Bloom-Richardson's histological grade I (tubule formation:1, nuclear pleomorphism:2, mitosis:1) 3) intraductal component > 30% 4) EIC(extensive intraductal component): positive 5) no vascular permeation 6) ER(+), PR(+), CerB2(-) 7) nipple and areola: free of tumor 8) overlying skin: free of tumor 9) underlying fascia: free of tumor	1	2	T1cN1aM0 (II A)	ER:+ PR: + C erb B2: -
6	A	11			Non-neoplastic from C1,2	non-neoplastic from C1,2				
7	B	1,2	f	70	Infiltrating ductal carcinoma	Breast, Frozen Excision: Infiltrating ductal carcinoma, nuclear grade 2, histologic grade 1. (tubule formation 2, mitotic grade 1) according to Bloom and Richardson and intraductal component less than 25%	1	2		

A202 (II): Breast cancer tissues

No.	Coordinate		Sex	Age	Key Word	Histological Diagnosis	HG	NG	TNM Stage	IHC
8	B	3,4	f	40	Infiltrating ductal carcinoma	Breast, left, modified radical mastectomy: Infiltrating ductal carcinoma, 1) black's nuclear grade 3 (well differentiated) 2) modified Bloom-Richardson's histological grade I (tubule formation: 2, nuclear pleomorphism: 1, mitosis: 1) 3) nipple and areola: free of tumor 4) overlying skin: free of tumor 5) underlying fascia: close to tumor (within 1 mm) 6) regional lymph node, axillary (3/15), level II (0/1), level III (0/1) : (3/17): tumor metastasis in 3 out of 15 nodes(pN1bi)	1	3	T2N1bM0 (II B)	ER:+ PR: + C erb B2: -
9	B	5,6	f	67	Infiltrating ductal carcinoma	Breast, left, radical mastectomy: Infiltrating ductal carcinoma 1) size: 5x4x3cm 2) black's nuclear grade 3(well differentiated) 3) modified Bloom-Richardson's histological grade I (tubule formation: 3, nuclear pleomorphism: 1, mitosis: 1) 4) no vascular invasion 5) deep fascial margin involved by tumor 6) no intraductal component 7) nipple and areola: free of tumor 8) overlying skin: free of tumor 9) regional lymph node, axillary (0/16), level II (0/2) : (0/18): free of tumor	1	3	T2N0M0 (II A)	ER:+ PR: + C erb B2: -
10	B	7,8	f	45	Infiltrating ductal carcinoma	Breast, left, modified radical mastectomy: 1) Infiltrating ductal carcinoma, nuclear grade 3 (well differentiated), histologic grade I 2) Intraductal component: 10-15% 3) nipple and areola: free of tumor 4) overlying skin: free of tumor 5) underlying fascia: free of tumor 6) lymph nodes, axillary (6/14): tumor metastasis to 6 out of 14 lymph nodes with perinodal soft tissue extension(pN1biii) 7) lymph nodes, unlabelled (0/5): free of tumor	1	3	T3N2aM0 (III A)	ER:+ PR: + C erb B2: -

A202 (II): Breast cancer tissues

No.	Coordinate		Sex	Age	Key Word	Histological Diagnosis	HG	NG	TNM Stage	IHC
11	B	9.1	f	67	Infiltrating ductal carcinoma	Breast, right, modified radical mastectomy: Infiltrating ductal carcinoma 1) Black's nuclear grade 3 (well differentiated). 2) Modified Bloom-Richardson's histological grade I (tubule formation: 1, nuclear pleomorphism: 1, mitosis:1). 3) with features of cribriform carcinoma. 4) intraductal component: <10%. 5). frequent perineural invasion. 6) no lymphatic permeation. 7) nipple and areola: free of tumor. 8) overlying skin: free of tumor. 9) underlying fascia: free of tumor. 10) regional lymph node, axillar (0/18), level II (0/6), level III (0/0): (0/24): free of tumor.	1	3	T2N0M0 (II A)	ER:+ PR: + C erb B2: -
12	B	11			Non-neoplastic from E7,8	non-neoplastic from E7,8				
13	C	1,2	f	67	Infiltrating ductal carcinoma	Breast, left, partial mastectomy: Infiltrating ductal carcinoma, nuclear grade 3 (well differentiated), histologic grade I with minimal intraductal component (about 5%)	1	3	T2N1aM0 (II A)	ER:+ PR: - C erb B2: -
14	C	3.4	f	34	Infiltrating ductal carcinoma	Breast, right, modified radical mastectomy: Infiltrating ductal carcinoma 1) size 2) black's nuclear grade 1 (poorly differentiated) 3) modified Bloom-Richardson's histological grade II (tubule formation: 2, nuclear pleomorphism: 3, mitosis: 2) 4) frequent bizarre nuclear change and stromal fibrosis, due to previous chemotherapy 5) no lymphatic permeation 6) intraductal component: less than 15% 7) focal involvement of deep dermis of the skin 8) focal extension to skeletal muscle 9) nipple and areola: pagetoid involvement of lactiferous ducts and peri-lactiferous ductal invasion of infiltrating ductal carcinoma 10) underlying fascia: free of tumor 11) regional lymph nodes: axillary (6/6), level II+III (2/2) : (8/8): tumor metastasis in all 8 nodes(pN2: Metastasis to ipsilateral axillary lymph nodes that are fixed to one another with extensive perinodal structure)	2	1	TxN2aM0 (III)	ER:+ PR: + C erb B2: -

A202 (II): Breast cancer tissues

No.	Coordinate		Sex	Age	Key Word	Histological Diagnosis	HG	NG	TNM Stage	IHC
15	C	5.6	f	36	Infiltrating ductal carcinoma	Breast, right, mastectomy: Infiltrating ductal carcinoma 1) black's nuclear grade: 1 (poorly differentiated) 2) modified Bloom-Richardson's histological grade II (tubule formation:1, nuclear pleomorphism:3, mitopsis:2) 3) rare intraductal component (< 5%) 4) no lymphatic permeation 5) resection margins, all: free of tumor, see note Note: The tumor is close to the posterior margin (about 5 mm)	2	1	T1cN0M0 (I)	ER:- PR:- C erb B2: -
16	C	7.8	f	62	Infiltrating ductal carcinoma	Breast, left, modified radical mastectomy: Post excisional biopsy status with residual infiltrating ductal carcinoma 1) black's nuclear grade 1 (poorly differentiated) 2) modified Bloom-Richardson's histological grade II (tubule formation: 3, nuclear pleomorphism: 3, mitosis: 1) 3) occasional lymphatic permeation 4) no intraductal component within the residual mass 5) extensive ductal carcinoma in situ(comedo carcinoma) in adjacent parenchyma 6) nipple and areola: free of tumor 7) overlying skin: free of tumor 8) underlying fascia: free of tumor 9) regional lymph node, axillary (0/1), level II (0/0) : (0/1): free of tumor	2	1	T1cN0M0 (I)	ER:- PR:weekly + C erb B2: +

A202 (II): Breast cancer tissues

No.	Coordinate		Sex	Age	Key Word	Histological Diagnosis	HG	NG	TNM Stage	IHC
17	C	9,10	f	67	Infiltrating ductal carcinoma	<p>1.Breast, left, simple mastectomy: Infiltrating ductal carcinoma 1) black's nuclear grade 2 (moderately differentiated) 2) modified Bloom-Richardson's histological grade II (tubule formation: 3, nuclear pleomorphism: 2, mitosis: 2) 3) intraductal component: about 15%. 4) ductal carcinoma in situ(occasionally with papillary feature) in adjacent parenchyme 5) no lymphatic permeation</p> <p>2.Breast, left, modified radical mastectomy: Postexcisional biopsy state with focal residual ductal carcinoma in situ 1) nipple and areola: free of tumor 2) overlying skin: free of tumor 3) underlying fascia: free of tumor 4) regional lymph node, axillary (0/12) : (0/12): free of tumor</p>	2	2	T2N1aM0 (II B)	ER:+ PR: + C erb B2: -
18	C	11			Non-neoplastic from F7,8	non-neoplastic from F7,8				
19	D	1,2	f	42	Infiltrating ductal carcinoma Mucinous carcinoma	<p>Breast, right, frozen biopsy: 1) infiltrating ductal carcinoma (1.8x1.5 cm); - black's nuclear grade 2(moderately differentiated), modified Bloom-Richardson's histological grade II (tubule formation:2,mitosis: 3, nuclear pleomorphism: 2) - intraductal component: about 10% - no vascular permeation</p> <p>2) mucinous carcinoma (1.5x1.3 cm) focally showing signet ring cell feature with prominent lymphatic permeation and perineural invasion</p>	2	2	T1cN0M0 (I)	ER:+ PR: focal week + C erb B2: -
20	D	3,4	f	46	Infiltrating ductal carcinoma	<p>Breast, left partial mastectomy: Infiltrating ductal carcinoma with prominent tubular differentiation, 1) black's nuclear grade 2 (moderately differentiated) 2) modified Bloom-Richardson's histological grade II (tubule formation: 1, nuclear pleomorphism: 2, mitosis: 3) 3) EIC(extensive intraductal component): positive 4) no lymphatic permeation 5) resection margin, anterior: free of tumor</p>	2	2	T1bN0M0 (I)	ER:+ PR: - C erb B2: +
21	D	5,6	f	66	Infiltrating ductal carcinoma	<p>Breast, left, lumpectomy: Infiltrating ductal carcinoma, nuclear grade 2, Histologic grade II without intraductal component</p>	2	2	T2N0M0 (II A)	ER:+ PR: + C erb B2: -

A202 (II): Breast cancer tissues

No.	Coordinate		Sex	Age	Key Word	Histological Diagnosis	HG	NG	TNM Stage	IHC
22	D	7,8	f	54	Infiltrating ductal carcinoma	Breast, right, mastectomy: Infiltrating ductal carcinoma, nuclear grade 2, Histologic grade II, without intraductal component	2	2	T2N0M0 (II A)	ER:+ PR: + C erb B2:focal +
23	D	9,10	f	38	Infiltrating ductal carcinoma	Breast, left, modified radical mastectomy: Infiltrating ductal carcinoma 1) black's nuclear grade 2 (moderately differentiated) 2) modified Bloom-Richardson's histological grade II (tubule formation: 3, mitosis: 1, nuclear pleomorphism: 2) 3) no lymphatic permeation 4) nipple and areola: free of tumor 5) overlying skin: free of tumor 6) underlying fascia: free of tumor 7) regional lymph nodes, axillary (5/27), level II (0/2), level III (0/3) : (5/32): tumor metastasis in 5 out of 32 nodes(pN1bii)	2	2	T3N2aM0 (III A)	ER:+ PR:+ C erb B2:- E cadherin:+
24	D	11			Non-neoplastic from G1,2	non-neoplastic from G1,2				
25	E	1,2	f	61	Infiltrating ductal carcinoma	Breast, frozen biopsy: Infiltrating ductal carcinoma histologic grade 2 by Nottingham modification of Bloom-Richardson grade (nuclear pleomorphism 2, tubule formation 2 (10-75%), mitotic count 2)			T1cN2aM0 (III A)	ER:+ PR:+
26	E	3,4	f	37	Infiltrating ductal carcinoma	Breast, frozen biopsy: Infiltrating ductal carcinoma (nuclear grade 2, Bloom and Richardson's histologic grade II)	2	2	T2N3M0 (III C)	ER:+ PR:+
27	E	5,6	f	35	Infiltrating ductal carcinoma	Breast, right, lumpectomy: 1) infiltrating ductal carcinoma, nuclear grade 1 (poorly differentiated), histologic grade III with minimal intraductal component (about 5%) 2) focal lymphovascular permeation of carcinoma 3) resection margins, medial and superior: involvement of ductal carcinoma in situ 4) resection margin, inferior and lateral: free of tumor	3	1	T1cN3aM0 (III C)	ER:+ PR: + C erb B2: -

A202 (II): Breast cancer tissues

No.	Coordinate	Sex	Age	Key Word	Histological Diagnosis	HG	NG	TNM Stage	IHC
28	E 7,8	f	36	Infiltrating ductal carcinoma Comedocarcinoma	Breast, right, total mastectomy: Infiltrating ductal carcinoma 1) size: 2x1.8x1.3 cm 2) black's nuclear grade 1 (poorly differentiated) 3) modified Bloom-Richardson's histological grade III (tubule formation: 3, nuclear pleomorphism: 3, mitosis: 3) 4) intraductal component within the mass of infiltrating ductal carcinoma: less than 5% 5) extensive ductal carcinoma in situ (comedocarcinoma) in adjacent parenchyme with scattered foci of microinvasion (separate from the main mass) 6) occasional lymphatic permeation 7) nipple and areola: free of tumor 8) underlying fascia: free of tumor 9) lymph nodes, axillary (2/8), level metastatic adenocarcinoma in 2 out of 8 nodes (size of metastatic tumor: 1.5 mm) (pN1a: only micrometastasis)	3	1	T1cN1aM0 (II A)	ER:- PR: - C erb B2: +
29	E 9,10	f	36	Infiltrating ductal carcinoma	1. Breast, left, modified radical mastectomy: Infiltrating ductal carcinoma, nuclear grade 1 (poorly differentiated), histologic grade III with extensive intraductal component (about 35%) 1) nipple and areola: free of tumor 2) overlying skin: free of tumor 3) underlying fascia: free of tumor 4) lymph nodes, axillary (0/31): free of tumor 2. Soft tissue, separately submitted as level II lymph node: free of tumor	3	1	T2N0M0 (II A)	ER:+ PR: + C erb B2: -

A202 (II): Breast cancer tissues

No.	Coordinate		Sex	Age	Key Word	Histological Diagnosis	HG	NG	TNM Stage	IHC
30	F	1,2	f	47	Infiltrating ductal carcinoma	Breast, left, modified radical mastectomy: Infiltrating ductal carcinoma, 1) black's nuclear grade 1 (poorly differentiated) 2) modified Bloom-Richardson's histological grade III (tubule formation: 3, nuclear pleomorphism: 3, mitosis: 3) 3) extensive intraductal component (EIC) positive 4) no lymphatic permeation 5) nipple and areola: free of tumor 6) overlying skin: free of tumor 7) underlying fascia: free of tumor 8) regional lymph node, axillary (24/32), level 2 (0/1), level 3 (1/2) : (25/35): metastatic adenocarcinoma in 25 out of 35 nodes (pN1biii: extranodal extension and metastasis < 2 cm)	3	1	T2N3aM0 (III C)	ER:+ PR: + C erb B2: +
31	F	3.4	f	37	Infiltrating ductal carcinoma	Breast, right, mastectomy: Infiltrating ductal carcinoma, 1) black's nuclear grade 1 (poorly differentiated) 2) modified Bloom-Richardson's histological grade III (tubule formation: 3, nuclear pleomorphism: 3, mitosis: 3) 3) no intraductal component 4) no lymphatic permeation 5) with clean surgical margins	3	1	T2N0M0 (II A)	ER:- PR: - C erb B2: -
32	F	5.6	f	64	Infiltrating ductal carcinoma Apocrine carcinoma	Breast, left, mastectomy: Infiltrating ductal carcinoma 1) black's nuclear grade 1 (poorly differentiated) 2) modified Bloom-Richardson's histological grade III (tubule formation: 3, nuclear pleomorphism: 3, mitosis: 2) 3) with prominent apocrine differentiation (so called apocrine carcinoma) 4) intraductal component < 5% 5) ductal carcinoma in situ (with apocrine feature) in adjacent parenchyme 6) no lymphatic permeation 7) marked peritumoral lymphoplasmacytic infiltration 8) nipple and areola: free of tumor 9) overlying skin: free of tumor 10) regional lymph node, axillary (2/18): tumor metastasis in 2 out of 18 nodes 11) underlying fascia: free of tumor	3	1	T2N1aM0 (II B)	ER: - PR:- C erb B2:+ P53:+ CEA:+ BRST-2:+

A202 (II): Breast cancer tissues

No.	Coordinate		Sex	Age	Key Word	Histological Diagnosis	HG	NG	TNM Stage	IHC
33	F	7,8	f	34	Infiltrating ductal carcinoma	Breast, right, lumpectomy: Infiltrating ductal carcinoma, nuclear grade 2, Histologic grade III with minimal intraductal component (less than 5%) 1) resection margins, superior, inferior, and medial: free of tumor 2) resection margin, lateral: free of tumor	3	2	T1cN1aM0 (II A)	ER:+ PR: + C erb B2:-
34	F	9,10	f	37	Infiltrating ductal carcinoma	Breast, frozen biopsy: Infiltrating ductal carcinoma with 1) Bloom and Richardson's grade III 2) intraductal component over 25% 3) marked lobular cancerization			T2N0M0 (II A)	
35	G	1,2	f	40	Invasive ductal carcinoma Papillary carcinoma	Breast mass(#2), right, excisional biopsy(FS): Invasive ductal(papillary) carcinoma, modified Bloom-Richardson grade 2, tumor size 2.5 cm	2		T2N0M0 (II A)	ER:+ PR: + C erb B2:-
36	G	3,4	f	42	Papillomatosis Papillary carcinoma Ductal carcinoma in-situ	Breast, right, lumpectomy: 1) multifocal non-invasive(intraductal) papillary carcinoma with foci of atypical papillomatosis 2) non-papillary ductal carcinoma in situ, multifocal, with extensive lobular cancerization 3) resection margin, medial: involvement of tumor 4) resection margins, inferior and lateral: presence of atypical ductal hyperplasia 5) resection margin, superior: free of tumor			T2N0M0 (II A)	
37	G	5,6	m	75	Papillary carcinoma	Breast, right, mastectomy: Invasive papillary carcinoma, invading into skin 1) nipple and areola: free of tumor 2) underlying fascia: tumor present within 1 mm from the margin 3) regional lymph node (0/12): free of tumor			T4bN0M0 (III B)	ER:+ PR: + C erb B2:-

A202 (II): Breast cancer tissues

No.	Coordinate		Sex	Age	Key Word	Histological Diagnosis	HG	NG	TNM Stage	IHC
38	G	7,8	f	41	Papillary carcinoma	Breast, left, partial mastectomy: Papillary carcinoma with osteoclastic-type giant cells Note: There is questionable evidence of minimal focal invasion Flow cytometry result: Tissue type: Breast Model type: Diploid DIPLOID: 100.00% Dip G0-G1: 94.25% at 44.60 Dip G2-M : 2.82% at 89.20 Dip S: 2.93% G2/G1: 2.00 Dip %CV: 11.67 Total S-Phase: 2.93%			T1cN0M0 (I)	ER:+ PR: + C erb B2: -
39	G	9.1	f	40	Ductal carcinoma in-situ Papillary carcinoma	Breast, right, biopsy: 1) ductal carcinoma in situ 2) papillary carcinoma			T1bN0M0 (I)	ER:+ PR: + C erb B2:-
40	H	1,2	f	61	Intraductal carcinoma Papilloma Ductal carcinoma in-situ Papillary carcinoma	Breast, left, excision: Intraductal carcinoma and noninvasive papillary neoplasm (carcinoma arising in papilloma), with involvement of surgical margin			TxN0M0	ER:+ PR: + C erb B2:-
41	H	3,4	f	62	Papillary carcinoma	Breast, excision: Papillary carcinoma, intraductal with focal microinvasion			T1cN0M0 (I)	ER:- PR:- C erb B2:+

A202 (II): Breast cancer tissues

No.	Coordinate	Sex	Age	Key Word	Histological Diagnosis	HG	NG	TNM Stage	IHC			
42	H	5,6	f	62	Papillary carcinoma	<p>Breast, right, radical mastectomy: Invasive papillary carcinoma, moderately differentiated with 1) histologic grade 2/3 2) nuclear grade 2/3 3) tumor size: 11 cm 4) tumor necrosis: moderate 5) calcification: minimal 6) invasion of dermis but not epidermis 7) involvement of lactiferous duct 8) dermal lymphatic invasion 9) focal vascular invasion 10) attachment but not infiltration to the pectoralis major muscle 11) resection margin: free of tumor 12) lymph node, axillary: microscopic metastatic in two out of 46. (level I (0/9), level II (0/2), axillary (2/35)) EM> The tumor is composed of tightly apposed elongated cells containing ovoid nuclei. Nuclei have marginal chromatin condensation and reveal one or two prominent nucleoli. Luminal borders of papillary structure show moderately developed short microvilli. Each cell is joined by desmosomes. Cytoplasm is filled with numerous organelles, mitochondriae, free ribosomes, short RERs, lysosomes and a few lipid droplets. Intracellular lumens are occasionally found. Myoepithelial cells are present.</p> <p>< Cell cycle Analysis > . Sample: fresh specimen. . Model: SFIF . Events: 18002 . C.V: 5.3 . Cell cycle statistics: phase percent G 73.8 S 25.0 G2+M 1.2</p>			2,3	2,3	T4aN1M0 (III B)	ER: + PR:focal+
43	H	7,8	f	55	Infiltrating lobular carcinoma	<p>Breast, right, modified radical mastectomy: In situ and infiltrating lobular carcinoma (tumor size 2.5 cm) with focal extension to one of the lactiferous ducts of nipple without epidermal involvement. Level I axillary (0/10), level II and III (0/3) and interpectoral lymph nodes (0/1) are free of neoplastic</p>					T2N0M0 (II A)	
44	H	9,10	f	78	Infiltrating lobular carcinoma	<p>Breast, frozen biopsy: Infiltrating lobular carcinoma with LCIS</p>					T1cN0M0 (I)	ER:+ PR:- C erb B2:+

A202 (II): Breast cancer tissues

No.	Coordinate		Sex	Age	Key Word	Histological Diagnosis	HG	NG	TNM Stage	IHC
45	I	1,2	f	43	Cystosarcoma phyllodes Phyllodes tumor Malignant tumor	Breast, left, excision: Cystosarcoma phyllodes, malignant, margins involved by neoplasm				
46	I	3,4	f	37	Phyllodes tumor	BREAST: Frozen diagnosis, phyllodes tumor. final diagnosis, phyllodes tumor, low malignancy Note: Mitotic rate is 7-8/10 HPF. but invasion of margin and overt sarcomatous area are not noted. close follow-up is recommended.				
47	I	5,6	f	35	Phyllodes tumor Cystosarcoma phyllodes malignant	Breast, right, excision: Phyllodes tumor, malignant with involvement of margins				
48	I	7,8	f	54	Infiltrating lobular carcinoma	Breast, left, lumpectomy: Infiltrating lobular carcinoma (size 1.3x1.0 cm) resection margins, inferior and lateral: free of tumor			T1cN1aM0 (II A)	ER:+ PR:+ C erb B2:- E cadherin:-
49	I	9,10	f	43	Infiltrating lobular carcinoma	Breast, right, modified radical mastectomy: Infiltrating lobular carcinoma with occasional lymphatic permeation 1) nipple and areola: free of tumor 2) overlying skin: free of tumor 3) underlying fascia: free of tumor 4) regional lymph node, axillary level I (1/7), level II (3/3) : (4/10): metastatic lobular carcinoma in 4 out of 10 nodes (the largest metastatic tumor measures 8x3 mm in size at level I)			T1cN2aM0 (III A)	